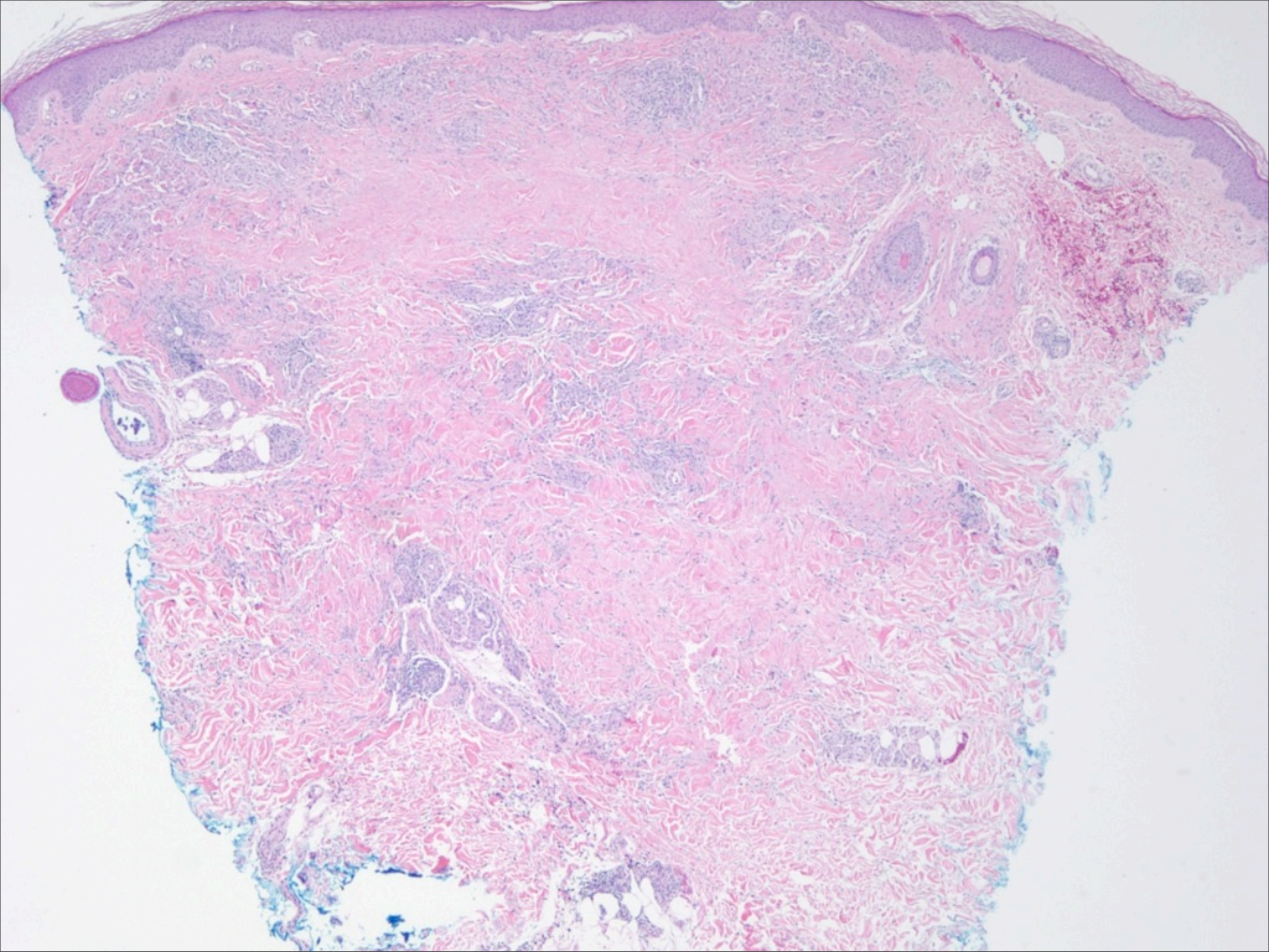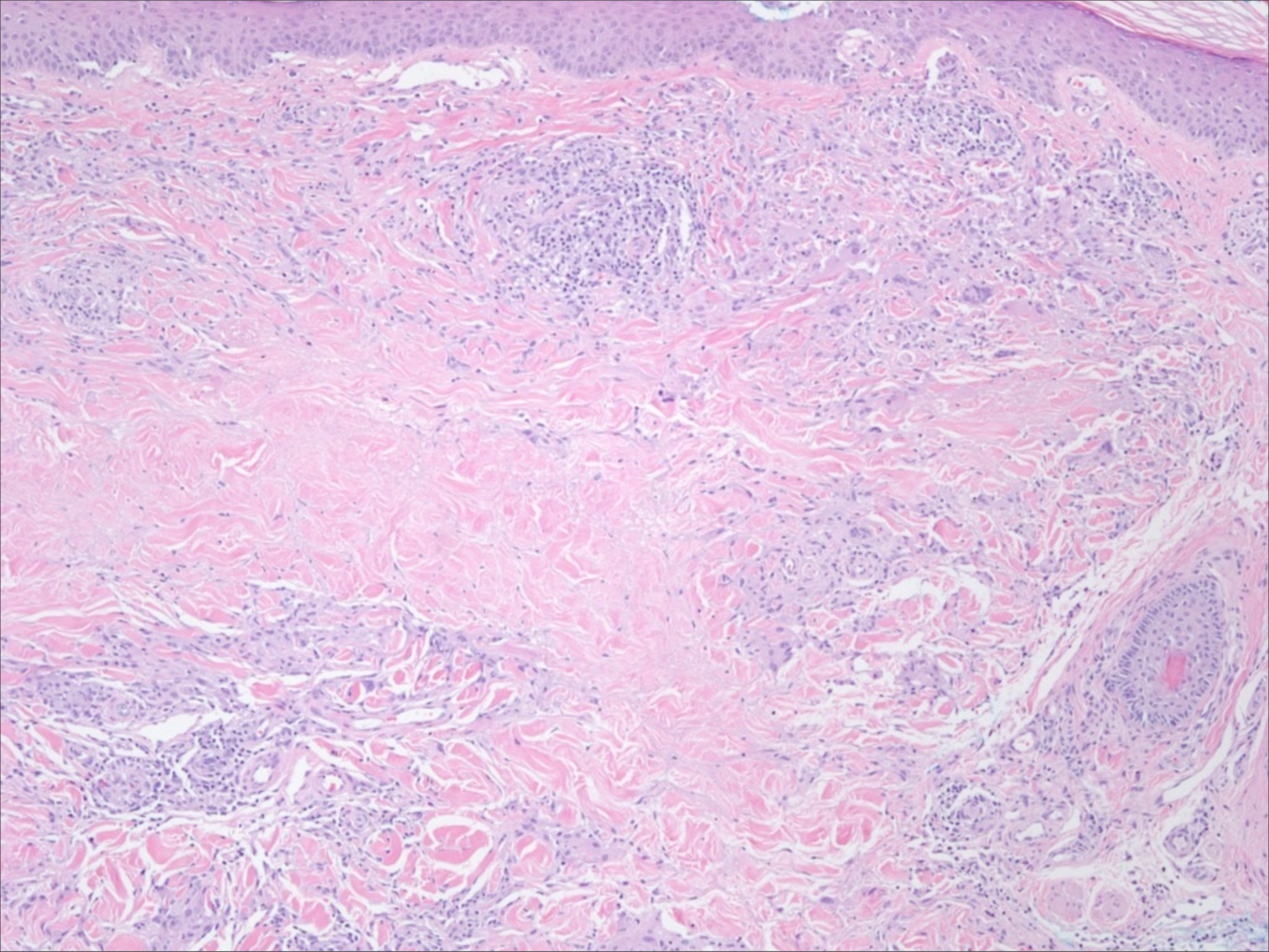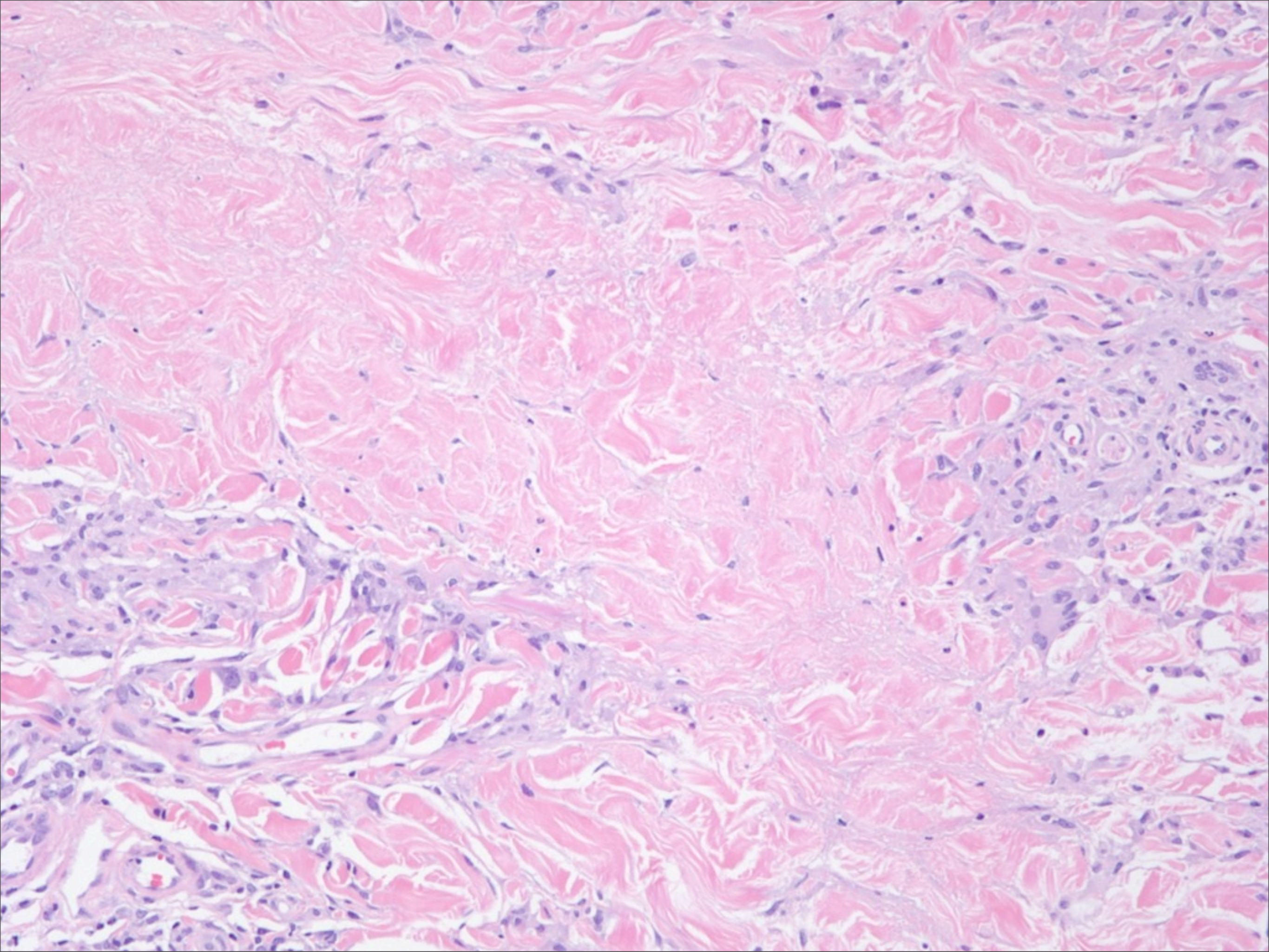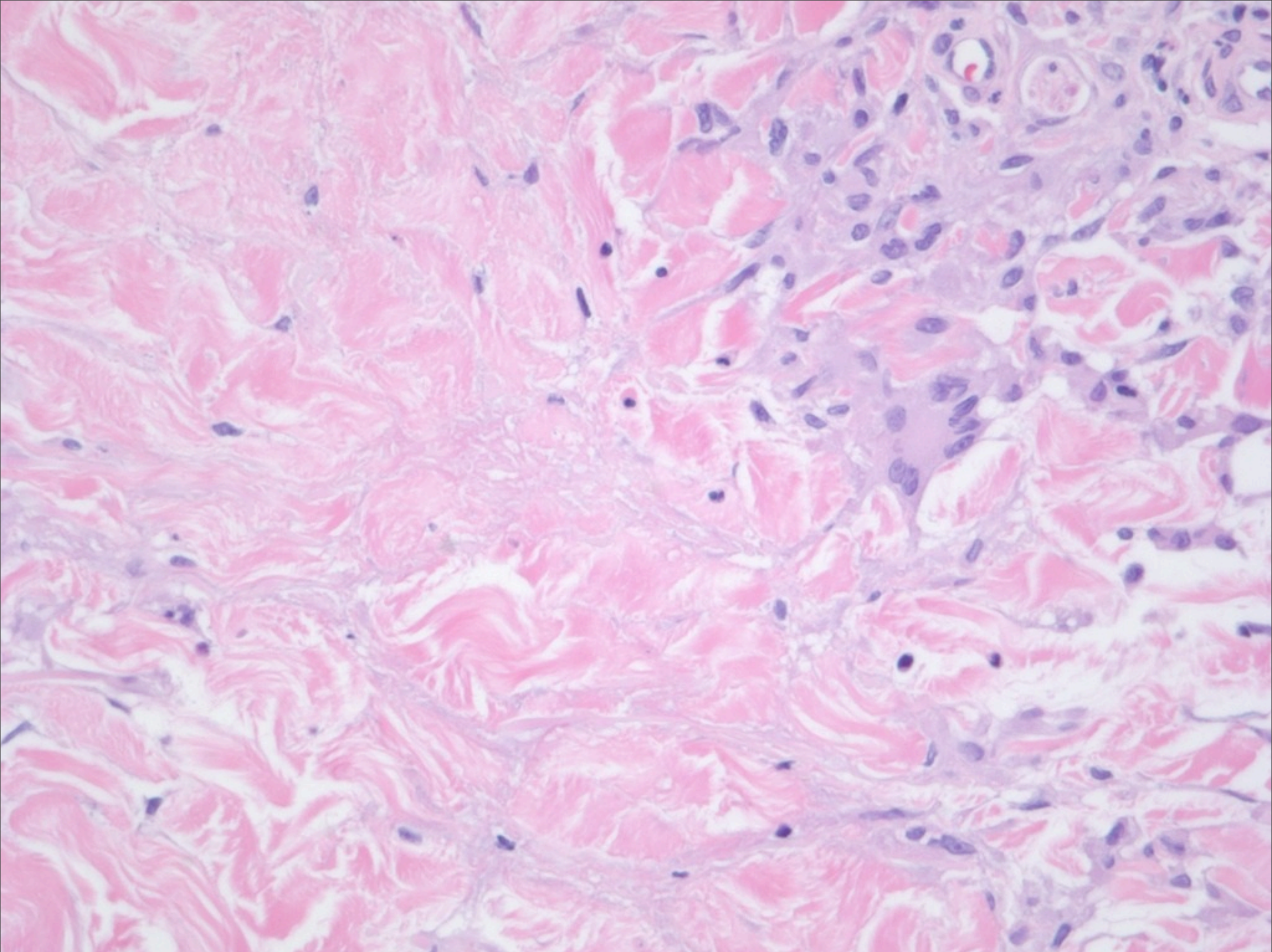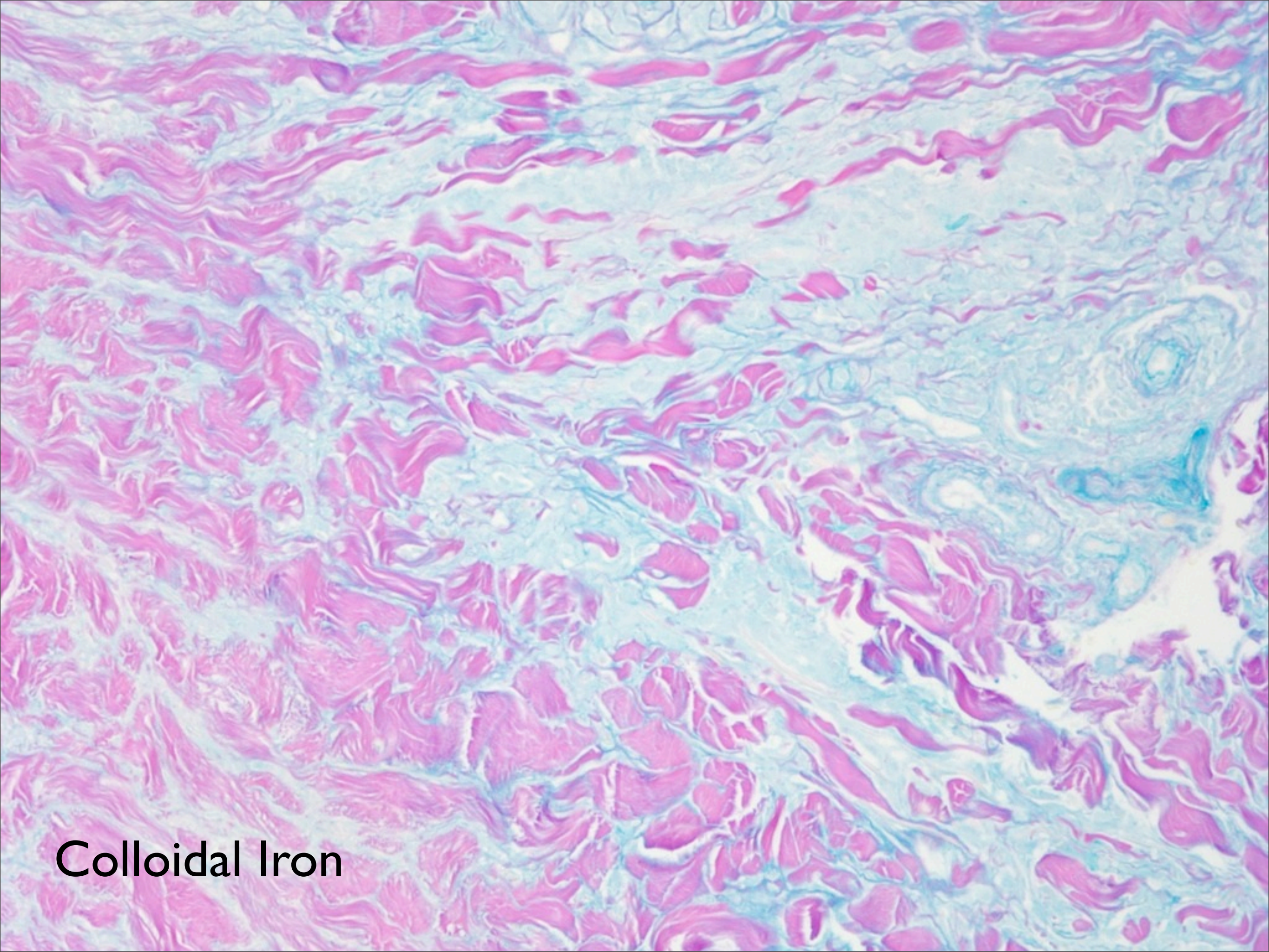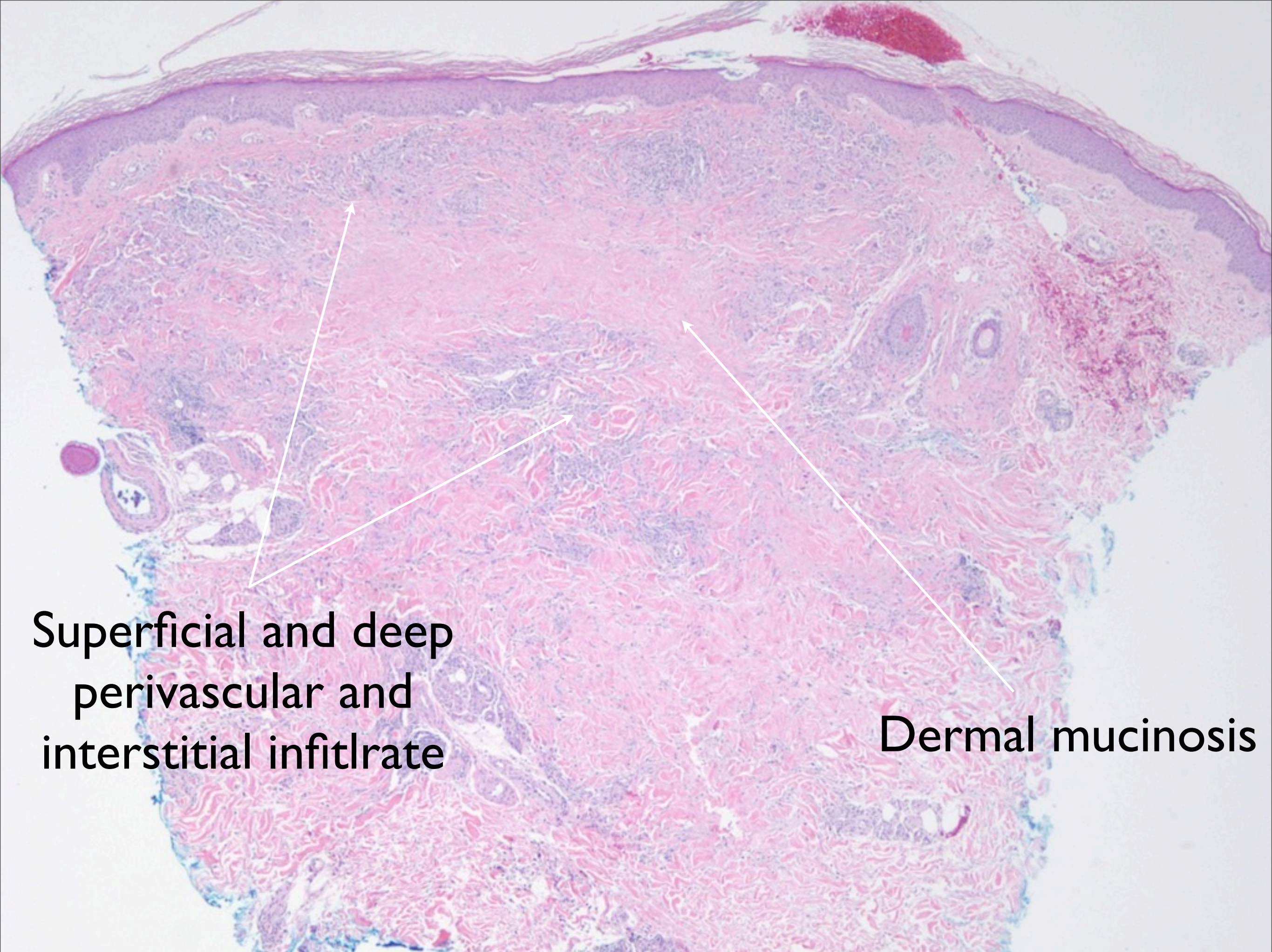


Colloidal Iron

What is the best diagnosis?

- Granuloma annulare
- Necrobiosis lipoidica
- Necrobiotic xanthogranuloma
- Reticular erythematous mucinosis
- Necrotizing sarcoidosis

Granuloma Annulare



**Superficial and deep
perivascular and
interstitial infiltrate**

Dermal mucinosis